



Research Article

Combining an Acidic Compound and NPWT: Debridement and Granulation in Leg and Foot Ulcers

Michel H E Hermans*

President Hermans Medical Consulting, Hoorn, the Netherlands

***Corresponding author:** Michael H E Hermans, President Hermans Medical Consulting, Hoorn, Smetanahof 41, 1628SR Hoorn, the Netherlands

Citation: Hermans MHE (2022) Combining an Acidic Compound and NPWT: Debridement and Granulation in Leg and Foot Ulcers. Ann Case Report. 7: 1101. DOI: 10.29011/2574-7754.101101

Received Date: 21 December 2022; **Accepted Date:** 24 December 2022; **Published Date:** 27 December 2022

Abstract

The typical skin ulcer has been in existence for a while and is covered with necrosis and biofilm. These characteristics play a role in the chronicity of these ulcers and, therefore, the lesions should be debrided so that granulation formation, an essential step for healing by secondary intention, can start. **Hypothesis:** Debridement and subsequent granulation are supported by the combination of topical desiccation agent (TDA, Debrichem, DEBx Medical, Rotterdam, the Netherlands) and NPWT. TDA is a new debriding compound that works through desiccation: biological materials denature and coagulate together and tend to rapidly separate from the underlying tissues, thus clearing the way for granulation. NPWT has been shown to contribute positively to several aspects of the healing process as well, including the formation of granulation tissue. A prospective study was conducted to assess whether the combination of TDA and NPWT would support the development of granulation tissue. **Results:** 12 patients with different types of foot- and leg ulcers (average size: 308 cm², average age: 13 months) participated in the study. Five of the lesions were venous leg ulcers, two were arterial, and one was of mixed venous/arterial origin. One lesion was post trauma (unknown etiology: N=3). All patients reached complete granulation in, on average, 13,2 days (range: 7-21). **Conclusion:** The study indicates that the combination of TDA with NPWT is successful in removing biofilm and necrosis and supports the rapid development of granulation tissue, thus contributing to overall faster healing.

Keywords: Arterial ulcer; Debridement; NPWT; Post-trauma ulcer; Topical desiccation agent; Venous ulcer

Introduction

Ulcers of the legs and feet lead to serious morbidity and a significant reduction of the patient's quality of life [1 2] while their socioeconomical impact is high. For example, approximately 8% of diabetic Medicare beneficiaries have a foot ulcer [3, 4] and the cost of treatment of these ulcers in the US for patients in the Medicare system is estimated to be between 9 and 13 US\$ billion/year (2019 data) [5].

Venous leg ulcers are estimated to occur in approximately 1% of the US population [6].

Suffering from such an ulcer increases the cost of care for a

patient on Medicare with, on average, \$6.391 per year (2014 data) [7]. In the UK, the direct cost of managing a patient with a venous leg ulcer is estimated to be £ 7,706, which, for all patients with such an ulcer taken together, represents an annual cost of more than 2 billion pounds to the healthcare system [8].

Many typical skin ulcers such as venous leg ulcer and diabetic foot ulcers are, depending on their type, characterized and/or caused by aspects such as fibrin deposition, local oedema, hypoxia, fibrosis and microcirculatory problems and these factors also contribute to healing being stalled in a (hyper) inflammatory state [9]. The typical ulcer is covered with necrosis and a biofilm. These two characteristics play role in the chronicity of these ulcers [10], since they also contribute to the hyperinflammatory wound environment [11-17].

Thus, treatment of these lesions should be directed at ridding them of the detrimental effects of infection, biofilm, and necrosis [17-26] and to return the inflammatory process to its “normal” levels. Therefore, debridement is necessary [19, 22] so that granulation tissue can start developing. This is an essential step for healing by secondary intention [27, 28] which is how most of these lesions heal.

Many therapies and methods are used to debride a lesion, including surgical, hydrosurgical, enzymatic, biosurgical (with maggots), biological, and ultrasonic techniques [1, 22, 29-32]. All have their own benefits and drawbacks [18, 29-31], such as a slow level of activity (enzymes and autolysis), and complexity (hydrosurgery) [33, 34]. Surgical debridement is quick and efficient [35-38] but requires specific expertise at a high cost and needs to be performed in a specialized environment (i.e. operating theatre) [36].

Topical desiccation agent (TDA) is a new compound that has been designed as an alternative to surgical debridement. It works through the desiccating properties of its main component, methane sulfonic acid, and removes biofilm and necrosis effectively and rapidly. In contrast to surgical debridement, TDA does not need a great deal of specific expertise, nor a specialized setting [37-41].

The desiccation effect of the agent is virtually immediate; biological materials denature and coagulate together and tend to rapidly separate from the underlying tissues. There is no specific requirement for dressings or other interventions after application of TDA: these can be used at the physician’s discretion.

Negative pressure wound therapy (NPWT) generates a number of local effects on the wound bed, including induction of perfusion changes, and tissue micro- and macro-deformation (which stimulate the wound healing cascade) [42-44]: these effects contribute positively to several aspects of the healing process, including the formation of granulation tissue through increased angiogenesis [45]. In a prospective study on patients with pressure ulcers, diabetic foot ulcers and venous leg ulcers, NPWT was shown to be a positive adjunct to surgical debridement, promoting wound healing [46, 47]. We decided to assess whether the application of TDA, followed by the use of NPWT, would support the development of granulation tissue..

Methods and Materials

A prospective, non-comparative study was being conducted to assess the time to complete granulation of leg- and foot ulcers. The study was approved by the ethical committee of the Villa Berica Hospital in Vicenza (Italy), in line with the declaration of Helsinki [48].

The main inclusion criterion for this study was the presence of an ulcer that had not responded to ambulatory treatment for a period of at least four weeks and that was clinically infected. The

infection was confirmed with wound cultures. Patients had to be older than 18 years.

Exclusion criteria to the study were patients who were pregnant or in whom the leg with the ulcer was ischemic without being revascularized. Osteomyelitis, present underneath the ulcer, was another exclusion criterion, as were exposed cartilage, signs of systemic infection (fever, septic shock, etc.), and the patient having a poor life expectancy.

Consecutive patients who would fit the exclusion- and inclusion criteria and who were admitted to the clinic for elective surgical debridement were enrolled in this study, and their surgery was substituted by treatment with TDA.

The treatment protocol included basic cleaning of the wound and the periwound skin with saline and subsequent application of TDA over the lesion and about 1cm onto the periwound skin. After 60 seconds the agent was diluted and removed by rinsing with water or saline (because of the short exposure period the periwound skin, with its low water content of the stratum corneum, is protected from the desiccating effects of TDA). The wound was dried and NPWT (VAC, KCI/3M, St. Paul, Minn) was applied in the same session. The protocol forbode the use of antibiotics, prior or after the application of TDA.

NPWT was used with standard foam at -125 mm Hg with five minutes “on” time and two minutes “off” time. Dressing changes took place every two to four days and NPWT was stopped at seven days post-application of TDA. The lesion was further dressed with vaseline gauze until granulation formation, the primary outcome of this study, was complete.

The primary objective of the study was to assess the efficacy of TDA, namely to what extent removal of biofilm and necrosis would lead to complete granulation and how quickly granulation would be complete. The secondary objective was to assess safety, by recording possible adverse events and side effects of the treatment methods. Time to complete reepithelialization was not part of the study since the study device is not designed to support this particular healing phase.

The first patient was enrolled in March 2021. After six months, the study had to be put on hold, since the clinic was turned into a “Covid Hospital” and patients with non-Covid (related) pathology had to be treated elsewhere. Therefore, we are only presenting interim results of those patients with a complete record at the time of the hospital conversion.

Results

After they had given consent, ten female and two male patients participated in the study. The average age was 77,9 years (range: 55-91). Seven of the lesions were located on the left lower leg, and five on the right lower leg. Two patients had one ulcer on

each leg: for these two patients we chose the largest ulcers for participation in the data analysis (both on the right leg). Five of the lesions were venous leg ulcers, two were arterial, and one was of mixed venous/arterial origin. One lesion was post trauma and for three the origin was not known (Figure I). Diagnoses were established clinically and, where and when necessary, with additional methods such as ABI and ultrasound. No biopsies were taken.

Figure I

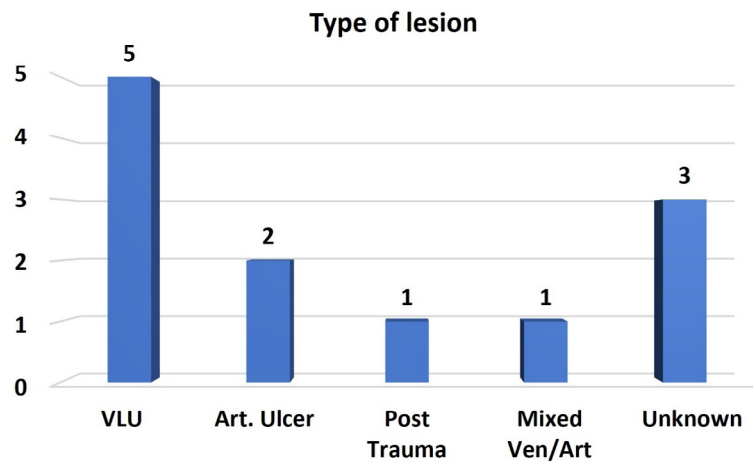


Figure 1: Five of the lesions were venous leg ulcers, two were arterial, and one was of mixed venous/arterial origin.

The average size was 308 cm² (range: 60-1750) (Figure II). On average, the lesions had been in existence for 13 months (range: 4-48) (Figure II), during which period they were treated with a plethora of varied materials.

Figure II

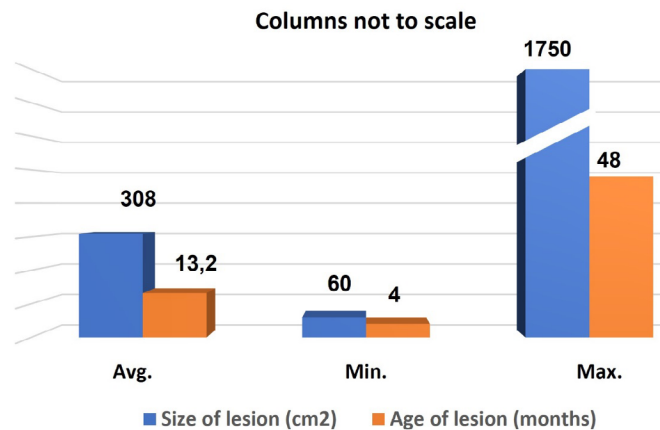


Figure 2: the lesions had been in existence for 13 months (range: 4-48).

Percutaneous endovascular revascularization was performed in two patients, one day prior to the application of TDA. In two patients, necrotic tendons were excised just prior to, but in the same session as the application of TDA.

For the procedure, a peripheral nerve block was used in seven patients, a spinal block in four patients and a topical 10% lidocaine cream in the remaining one patient. The type of anaesthesia was determined, among other factors such as a patients age and general condition, by wound size and location and the level of pain expected. All patients reached complete, visually assessed, granulation in, on average, 13,2 days (range: 7-21) (Figure III, IV).

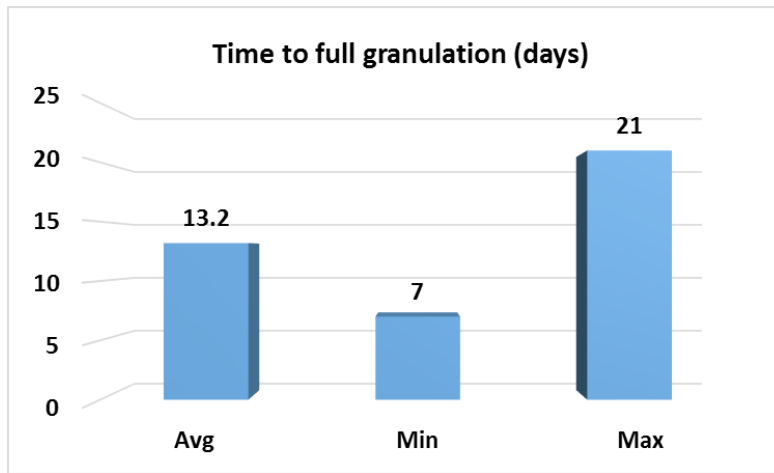
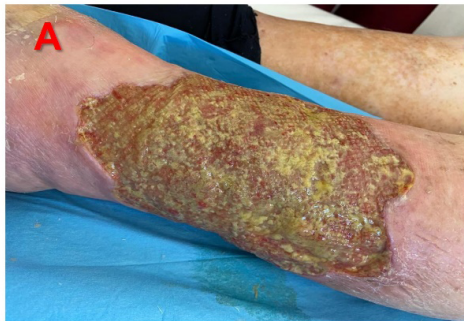
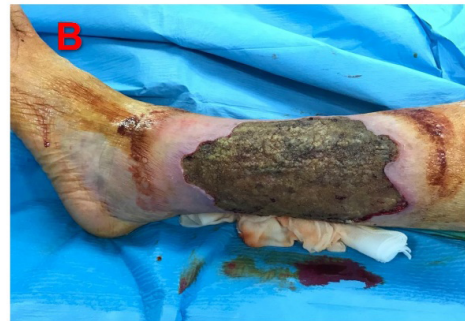
Figure 3: visually assessed, granulation in, on average, 13,2 days (range: 7-21).

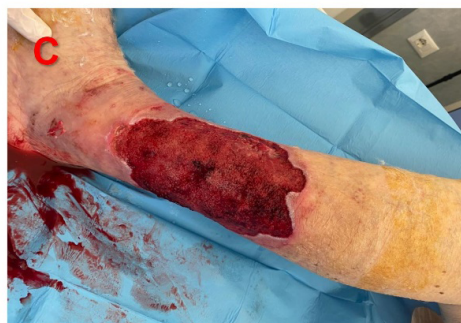Figure IV



Ulcer on left lower leg, prior to application of TDA



Aspect of denaturation, effect after application of TDA



10 days post application of TDA: granulation complete

Clinical reinfection, confirmed through a culture, occurred in one of the patients, after the lesion had completely granulated. For this patient, TDA treatment with subsequent NPWT was used again. This second application, nor the course of the wound healing process, was integrated into the calculations presented in this paper since complete granulation had already occurred.

Two patients took medications, known to interfere with wound healing (azathioprine (N=1), prednisone (N=1)).

All patients suffered from hypertension. In addition, four were diabetic and three patients suffered from hypercholesterolemia. Other concomitant conditions and diseases that each present in one patient were severe Vit D deficiency, severe obesity, lymphedema of the lower limbs, COPD, scleroderma, and depression.

When granulation was complete, the lesions were treated with an autologous split skin graft (N=2), or a meshed epidermal substitute (equine pericardium, HealingMesh, BioSynth Life-Sciences, Gossolengo, Italy) (N=3). In seven patients vaseline gauze, changed weekly, was used until reepithelialization was complete.

Discussion and Limitations

Many chronic lesions are notoriously difficult to heal, due to a series of internal and external factors that create a difficult healing environment. Internal factors are diverse, sometimes virtually impossible to control (i.e., microangiopathy in diabetes) and sometimes easy to correct (i.e., vein stripping, ablation in venous leg ulcers).

Biofilm and necrosis, virtually always present in chronic lesions, are two typical external factors that can be dealt with, however, primarily through proper debridement.

A biofilm protects bacteria from host immunities and provides a high level of protection against antimicrobial agents, both systemic [17] and, to large extent, topical [49, 50] as well. Biofilm per se contributes to the chronicity of ulcers because it contributes to and supports (hyper) inflammation [51, 52].

The presence of necrosis is also a major obstacle to (the initiation of) healing [21, 26, 41, 53]. Thus, necrosectomy (debridement) is a crucial step in wound care, necessary to eradicate these two detrimental effects on the wound healing process.

The lesions assessed in this study were relatively large compared to typical ulcers that are enrolled in clinical trials: often, a limitation to the size is one of the inclusion criteria [54, 55]. Similarly, in many trials medications or comorbidities that have a negative influence on wound healing are exclusion criteria: in this evaluation, this was not the case and, thus, many patients had these healing-compromising co-factors. In addition, per the protocol, all lesions had to be clinically infected to be allowed to enroll in the study. It is, therefore, fair to say that many of the lesions in this analysis were hard to heal, although a formal run-in period was not used to confirm this clinically.

In spite of these detrimental factors, granulation tissue, as mentioned a necessary proviso for healing by secondary intention, completely filled the lesions within, on average, 13.2 days with a combination therapy of TDA and NPWT. The granulation

tissue per se was healthy, i.e., without hypergranulation or other defects. As expected, within the short timeframe to granulation, no significant changes in wound size occurred. There were no test-treatment-related adverse events.

The single debridement (versus, typically, a number of surgical debridement interventions) and the fact that these interventions did not need to be performed in the OR was seen as a practical advantage, as was the fact that the number of dressing changes was limited. The administration of antibiotics was not allowed in the study and was, indeed, shown not to be necessary. All these aspects of TDA-NPWT interventions may contribute to cost savings. Indeed, in a recent study with venous leg ulcers as a model it was shown that the use of TDA is highly cost-effective [56].

All procedures were executed using some form of anaesthesia. It is important to realize that most debriding procedures also do (or at least would) require some form of pain relief. This is particularly also true for surgical debridement for which the TDA-NPWT application is seen as an alternative.

Further comparative studies are planned in different indications, where analyzing the speed and completeness of debridement, in different types of lesions, followed by granulation is the main objective.

The limitations for this study are inherent in the set-up: this was a single centre, small, prospective, non-comparative study with a number of patients with different diagnoses, ulcers at various anatomical locations, different comorbidities, and an unequal division of the patients' sex. Thus, the results obtained cannot necessarily be extrapolated to other settings. At the same time, biofilm and necrosis are virtually omnipresent in the type of lesions included in this study, and there is no specific reason why their removal should not be one of the major objectives in wound healing: after all, healing per secondary intention, the way these lesions typically heal, cannot start without a wound bed filled with granulation tissue [57-59]. Indeed, the removal of necrotic material or biofilm from chronic lesions was proven successful with our treatment protocol: after only one application of TDA and only one week of NPWT with subsequent wound treatment with vaseline gauze, all lesions reached complete granulation within, on average 13.2 days. Because the presence of granulation is essential for healing by secondary intention or, in certain types of eligible lesions, the success of some type of grafting, it is fair to say that fast granulation contributes to an overall faster healing process.

Conclusion

The combination of TDA and NPWT was proven successful in removing biofilm and necrosis from a series of relatively large lesions with different etiologies, in elderly patients with serious comorbidities and medications that negatively affect wound

healing. After the application of TDA and NPWT granulation tissue rapidly filled the lesions.

Using this treatment regime may contribute to cost reduction: shortening the period to complete granulation formation reduces the number of treatment visits and dressings needed. In addition, the debridement procedures themselves can be performed in a simple medical setting and do not need a high level of expertise which also may contribute to cost reduction.

These statements need to be, and will be, further explored in a comparative study.

Acknowledgement

M.H.E. Hermans is a consultant to DEBx Medical, BV. Rotterdam, the Netherlands.

References

1. Cooper MA, Qazi U, Bass E (2015) Medical and surgical treatment of chronic venous ulcers. *Semin Vasc Surg*; 28: 160-4.
2. Situm M, Kolic M, Redzepi G (2014) [Chronic wounds as a public health problem]. *Acta Med Croatica*; 68: 5-7.
3. Margolis DJ, Malay DS, Hoffstad OJ (2011) Prevalence of diabetes, diabetic foot ulcer, and lower extremity amputation among Medicare beneficiaries, 2006 to 2008: Data Points #1. *Data Points Publication Series*. Rockville (MD); 1.
4. Margolis DJ, Malay DS, Hoffstad OJ (2011) Incidence of diabetic foot ulcer and lower extremity amputation among Medicare beneficiaries, 2006 to 2008: Data Points #2. *Data Points Publication Series*. Rockville (MD); 2011.
5. Geraghty T, LaPorta G (2019) Current health and economic burden of chronic diabetic osteomyelitis. *Expert Rev Pharmacoecon Outcomes Res*; 19: 279-86.
6. Spear M (2012) Venous ulcers--an evidence-based update. *Plast Surg Nurs*; 32: 185-8.
7. Rice JB, Desai U, Cummings AK (2014) Burden of venous leg ulcers in the United States. *J Med Econ*; 17: 347-56.
8. Phillips CJ, Humphreys I, Thayer D (2020) Cost of managing patients with venous leg ulcers. *Int Wound J*; 17: 1074-82.
9. Kumar P, Khan IA, Das A (2022) Chronic venous disease. Part 1: pathophysiology and clinical features. *Clin Exp Dermatol*; 2.
10. Rajpaul K (2015) Biofilm in wound care. *Br J Community Nurs* 2015;Suppl Wound Care: 10-1.
11. Bianchi T, Wolcott RD, Peghetti A (2016) Recommendations for the management of biofilm: a consensus document. *J Wound Care*; 25: 305-17.
12. Loo WT, Sasano H, Chow LW (2007) Pro-inflammatory cytokine, matrix metalloproteinases and TIMP-1 are involved in wound healing after mastectomy in invasive breast cancer patients. *Biomed Pharmacother*; 61: 548-52.
13. Malone M, Bjarnsholt T, McBain AJ (2017) The prevalence of biofilms in chronic wounds: a systematic review and meta-analysis of published data. *J Wound Care*; 26: 20-25.
14. Percival SL, Hill KE, Williams DW (2012) A review of the scientific evidence for biofilms in wounds. *Wound Repair Regen*; 20: 647-57.
15. Wolcott RD, Rhoads DD, Bennett ME (2010) Chronic wounds and the medical biofilm paradigm. *J Wound Care*; 19: 45-6.
16. Wolcott RD, Rhoads DD, Dowd SE (2008) Biofilms and chronic wound inflammation. *J Wound Care*; 17: 333-41.
17. Snyder RJ, Bohn G, Hanft J (2017) Wound Biofilm: Current Perspectives and Strategies on Biofilm Disruption and Treatments. *Wounds*; 29: S1-S17.
18. Ayello EA, Cuddigan JE (2004) Debridement: controlling the necrotic/cellular burden. *Adv Skin Wound Care*; 17: 66-75.
19. Ayello EA, Dowsett C, Schultz GS (2004) TIME heals all wounds. *Nursing*; 34: 36-41.
20. Gethin G, Cowman S, Kolbach DN (2015) Debridement for venous leg ulcers. *Cochrane Database Syst Rev*; 2015: CD008599.
21. Hermans MHE (2019) An Introduction to Burn Care. *Adv Skin Wound Care*; 32: 9-18.
22. Manna B, Morrison CA (2019) Wound Debridement. *StatPearls*. Treasure Island (FL); 2019.
23. Mosti G (2013) Wound care in venous ulcers. *Phlebology*; 28: 79-85.
24. Percival SL, McCarty SM, Lipsky B (2015) Biofilms and Wounds: An Overview of the Evidence. *Adv Wound Care (New Rochelle)*; 4: 373-81.
25. Turns M (2013) Diabetic foot ulcer management: the podiatrist's perspective. *Br J Community Nurs*; 16-9.
26. Whitney J, Phillips L, Aslam R (2006) Guidelines for the treatment of pressure ulcers. *Wound Repair Regen*; 14: 663-79.
27. Zitelli J (1987) Wound healing for the clinician. *Adv Dermatol*; 2: 243-67.
28. Schultz GS, Barillo DJ, Mozingo DW (2004) Wound bed preparation and a brief history of TIME. *Int Wound J*; 1: 19-32.
29. Madhok BM, Vowden K, Vowden P (2013) New techniques for wound debridement. *Int Wound J*; 10: 247-51.
30. Marston W, Tang J, Kirsner RS (2016) Wound Healing Society 2015 update on guidelines for venous ulcers. *Wound Repair Regen*; 24: 136-44.
31. Patry J, Blanchette V (2017) Enzymatic debridement with collagenase in wounds and ulcers: a systematic review and meta-analysis. *Int Wound J*; 14: 1055-65.
32. Raposio E, Bortolini S, Maistrello L (2017) Larval Therapy for Chronic Cutaneous Ulcers: Historical Review and Future Perspectives. *Wounds*; 29: 367-73.
33. Bolton L, Corbett L, Bernato L (2006) Development of a content-validated venous ulcer guideline. *Ostomy Wound Manage*; 52: 32-48.
34. Mancini S, Cuomo R, Poggialini M (2018) Autolytic debridement and management of bacterial load with an occlusive hydroactive dressing impregnated with polyhexamethylene biguanide. *Acta Biomed*; 88: 409-13.
35. Ferrer-Sola M, Sureda-Vidal H, Altimiras-Roset J (2017) Hydrosurgery as a safe and efficient debridement method in a clinical wound unit. *J Wound Care*; 26: 593-99.

36. Gordon KA, Lebrun EA, Tomic-Canic M (2012) The role of surgical debridement in healing of diabetic foot ulcers. *Skinmed*; 10: 24-6.
37. Parizad N, Hajimohammadi K, Goli R (2021) Surgical debridement, maggot therapy, negative pressure wound therapy, and silver foam dressing revive hope for patients with diabetic foot ulcer: A case report. *Int J Surg Case Rep*; 82: 105931.
38. Rayala BZ (2020) Skin Ulcers: Surgical Management. *FP Essent*; 499: 29-37.
39. Hermans MH (2021) Healing results of chronic lesions after treatment with a new debriding agent, Topical Desiccation Agent. Symposium for Advanced Wound Care. National Harbor, MD (USA): on line: HMP, 2021.
40. Hermans MHE, Cogo A, Quint B (2020) Proof of principle: rapidly removing biofilm and necrosis in hard to heal ulcers using a hygroscopic chemical compound. Symposium for Advanced Wound Care, fall meeting. Las Vegas: HMP, 2020.
41. Cogo A, Bignozzi AC, Hermans MH (2020) A case series: a desiccation compound as a biofilm- and necrosis removing agent. 2020.
42. Lalezari S, Lee CJ, Borovikova AA (2017) Deconstructing negative pressure wound therapy. *Int Wound J*; 14: 649-57.
43. Borys S, Hohendorff J, Frankfurter C (2019) Negative pressure wound therapy use in diabetic foot syndrome-from mechanisms of action to clinical practice. *Eur J Clin Invest*; 49: e13067.
44. Ren SY, Liu YS, Zhu GJ (2020) Strategies and challenges in the treatment of chronic venous leg ulcers. *World J Clin Cases*; 8: 5070-85.
45. Liu Y, Tang N, Cao K (2018) Negative-Pressure Wound Therapy Promotes Wound Healing by Enhancing Angiogenesis Through Suppression of NLRX1 via miR-195 Upregulation. *Int J Low Extrem Wounds*; 17: 144-50.
46. Langer V, Bhandari PS, Rajagopalan S (2015) Negative pressure wound therapy as an adjunct in healing of chronic wounds. *Int Wound J*; 12: 436-42.
47. Ji S, Liu X, Huang J (2021) Consensus on the application of negative pressure wound therapy of diabetic foot wounds. *Burns Trauma*; 9: tkab018.
48. World-Medical-Association. WMA Declaration of Helsinki - Ethical Principles for Medical Research Involving Human Subjects: 64th WMA General Assembly; 2013.
49. Pugliese DJ (2016) Infection in Venous Leg Ulcers: Considerations for Optimal Management in the Elderly. *Drugs Aging*; 33: 87-96.
50. Bowler PG (2018) Antibiotic resistance and biofilm tolerance: a combined threat in the treatment of chronic infections. *J Wound Care*; 27: 273-77.
51. Goldberg SR, Diegelmann RF (2020) What Makes Wounds Chronic. *Surg Clin North Am*; 100: 681-93.
52. Versey Z, da Cruz Nizer WS, Russell E (2021) Biofilm-Innate Immune Interface: Contribution to Chronic Wound Formation. *Front Immunol*; 12: 648554.
53. Ahluwalia RS, Reichert ILH (2021) Surgical management of the acute severely infected diabetic foot - The 'infected diabetic foot attack'. An instructional review. *J Clin Orthop Trauma*; 18: 114-20.
54. Kavala AA, Turkyilmaz S (2018) Autogenously derived regenerative cell therapy for venous leg ulcers. *Arch Med Sci Atheroscler Dis*; 3: e156-e63.
55. Zelen CM, Serena TE, Denoziere G (2013) A prospective randomised comparative parallel study of amniotic membrane wound graft in the management of diabetic foot ulcers. *Int Wound J*; 10: 502-7.
56. Guest JF, Deanesi V, Segalla A (2022) Cost-effectiveness of Debrichem in managing hard-to-heal venous leg ulcers in the UK. *J Wound Care*; 31: 480-91.
57. Broughton G, 2nd, Janis JE, Attinger CE (2006) Wound healing: an overview. *Plast Reconstr Surg*; 117: 1e-S-32e-S.
58. Childs DR, Murthy AS (2017) Overview of Wound Healing and Management. *Surg Clin North Am*; 97: 189-207.
59. Velnar T, Bailey T, Smrkolj V (2009) The wound healing process: an overview of the cellular and molecular mechanisms. *J Int Med Res*; 37: 1528-42.